

# Hypoxic brain trauma causing blindness in a multiple gunshot wound patient: a challenging clinical scenario with a brief review of the literature

Benjamin Brod<sup>1</sup>, Tejas Patel<sup>1</sup>, Rebecca Hargett<sup>2</sup>, Berdith Lebrun<sup>2</sup>, Sultan S, Ahmed<sup>2,3,\*</sup>, Rolando Branly<sup>4</sup>, Syed A. A. Rizvi<sup>2,\*</sup>

<sup>1</sup> Ross University School of Medicine, Barbados

<sup>2</sup> College of Biomedical Sciences, Larkin University, Miami, Florida, USA

<sup>3</sup> JAS Medical Management, Miramar, Florida, USA

<sup>4</sup> Physical Sciences Department, Broward College, Davie, Florida, USA

## \* Corresponding authors

Syed AA Rizvi, MD, PhD, MPH, MBA. College of Biomedical Sciences, Larkin University, 18301 N Miami Ave, Miami, FL 33169, USA

Email: [srizvi@larkin.edu](mailto:srizvi@larkin.edu)

Sultan S Ahmed, MD. College of Biomedical Sciences, Larkin University, 18301 N Miami Ave, Miami, FL 33169, USA

Email: [sahmed@larkin.edu](mailto:sahmed@larkin.edu)

Received: 21 July 2023 Revised: 16 September 2023 Accepted: 16 September 2023 e-Published: 1 January 2024

## Abstract

**Background:** Cortical Blindness is most commonly caused by stroke or traumatic brain injury. The case study has the unique function of outlining the story of a young patient who incurred multiple gunshot wounds in an incident that ultimately transpired into a complete and permanent cortical blindness.

**Case presentation:** The present subject exhibits cortical blindness in the absence of either etiology. The proposed etiology is that of perioperative hypoxic seizures. Neuroanatomical and pathophysiological framework is established to elucidate the conditions surrounding the outcome.

**Discussion:** It is known that acute neuronal ischemia presents as drastically urgent to the tune of a five-minute intervention window, and it is learned that the prognosis of recovery from cortical blindness is statistically confined to an interval of around six months. Statistical context paves the way for a practical perspective on rehabilitation for patients with vision loss.

**Keywords:** Cortical Blindness, Relative Afferent Pupillary Defect, Visual Cognition.

## Introduction

A patient with cortical blindness may present with reported visual field disturbance, dimnesses of sight or complete loss. Arriving at a diagnosis of cortical blindness will first require adequate history taking. Document hypertension, diabetes, palpitations, fever, addiction, trauma and birth history when applicable. In physical examination, intently record pulse, blood pressure and temperature. Chiefly, cardiovascular etiology must be ruled out or remedied. A complete physical must include neurological and ophthalmological exam. Recall, that in cortical blindness, both pupillary light reflex and

oculomotor function are intact. Moreover, no relative afferent pupillary defect (RAPD) is noted in true cortical blindness. Attempt to elicit optokinetic nystagmus, ideally through use of a striped rotating drum, tracking the eyes' pursuit of one stripe and their saccade to the next. Optokinetic nystagmus will be absent in cortical blindness. Evaluating a patient with suspected cortical blindness involves obtaining typical measures such as CBC with ESR and CMP. Additionally, EKG and neuroimaging should be performed primarily to rule out thromboembolic event. CT scan is the initial test for neuroimaging, though an MRI remains superior in diagnosis. Continuing with more

specific visual testing, automated perimetry and evoked potential should be done with the patient's ophthalmologist.<sup>1</sup>

A functional and structural layout of the visual system will serve as framework for understanding a visual system impaired. For starters, light focused by the lens reaches the recipient tissue composed of various cell types responsible for converting light into a propagated electrical impulse. Such a process occurs at the retina. Central on the retina rests the macula, central on the macula: the fovea. The predominant cell type here and sole foveal photoreceptors are referred to as cones, responsible for manifesting and relaying sharp detail and color to vision. As such, more light is necessarily focused foveally. Straying peripherally, the predominant photoreceptors are referred to as rods. Rods function, more sensitive to depolarization, on low light; conveying night vision and spatial change at the cost of acuity and color.<sup>2</sup>

Rods and cones are the earliest neurons on the path to achieving visual cognition. These photoreceptors are linked via synapses to bipolar cells. Bipolar cells synapse respectively with ganglion cells. The retinal layer culminates at the optic disc as a collection of unmyelinated axons from ganglion cells. The optic disc, a retinal blind spot devoid of photoreceptors, marks the beginning of the optic nerve (CN II). Through the orbit's optic canal, alongside the ophthalmic artery, an eye's CN II meets the second CN II within the optic chiasm. Decussating caudally, the nerves are now optic tracts headed toward the lateral geniculate body (LGB) of the brain's thalamus. The LGB may now serve as a hub for visual data. Optic radiations continue caudally, ultimately to the primary visual cortex of the occipital lobe- denoted Brodmann's area 17 (BA 17). Notably, the LGB produces concurrent signals enroute to the superior colliculus, following now the succession of: the pulvinar, the secondary visual cortex (BA 18 & 19), the midbrain's Edinger-Westphal nucleus and finally to the oculomotor nerve (CN III) responsible for coordinating the eye's reflex motor signals.

Necessarily digressing, the LGB's optic radiation network to BA 17 grants visual consciousness. The optic radiations comprise thorough projection fibers implicating the temporal, parietal and occipital lobe as critical to visual

processing. For instance, optic radiations along the temporal lobe curve caudally to terminate ventral on the calcarine sulcus, at the lingula, thus forming Meyer's loop. The fibers of Meyer's loop convey signals for both eyes' superior visual field on the contralateral side. To contextualize, a theoretical lesion of the left hemisphere lingula will cause superior homonymous quadrantanopia in the right visual field. Similarly, the visual system is wired so that optic radiations coursing through the parietal lobe and terminating on the dorsal bank of the calcarine sulcus, the cuneus, convey the contralateral inferior visual field (for both eyes). Clinical example being a lesion of the right cuneus will cause inferior homonymous quadrantanopia in the left visual field.

The propagation and diffusion of visual data recruits specialized neurons present at varying layers of the visual cortex. Moving beyond the visual systems, theories postulate an interconnectedness of the nuanced responses to visual data that occur brain-wide. Pairing repeated stimulus to response allows a certain level of training involved with formulating learned representative heuristics. This concerted mental function renders sight to be effortlessly second nature.<sup>3</sup> Nonetheless, such delicate processes are naturally liable to become upset. Which is to say, compromising the neural network can lead to blindness in the absence of ophthalmologic insult. Commonly, the degree of cortical deficit is contingent upon blood flow to the existing structure. The visual cortex is specifically perfused by the posterior cerebral artery (PCA), a terminal branch of the basilar artery. Some notable branches of the PCA include the posterior temporal, parieto-occipital and the calcarine arteries. The occipital lobes may be more vulnerable to blood loss as it resides in a cerebral border zone. Hypoxic ischemia in the occipital lobe is known to cause cortical blindness, especially in patients who are not reperfused in a timely manner.<sup>1</sup> Reversibility of this condition likewise depends on how long the tissue has been starved of oxygen. The brain being particularly demanding of oxygen causes the timeline to become acutely significant. Ergo, the mechanism of cellular hypoxia proves instrumental in conceptualizing cortical blindness. Afterall, "time is brain".

Although an average adult's brain makes up only ~2% of a body's total weight, over 20% of energy reserves are allocated to it. Approximate normal cerebral blood flow (CBF) stands at 50 ml per 100 grams of brain tissue per minute. Ischemia is cited to occur when CBF drops below 40% of this normal. Importantly, CBF of 10 ml/100 g/min, causes irreversible damage to neurons and oligodendrocytes.<sup>4</sup> Cerebrovascular regulation allows protection from hypoxic injury by way of compensatory blood flow increase in the setting of reduced arterial oxygen. So proficient are these systems that respiratory hypoxia will not appreciably interfere with the brain's metabolism- given cardiac function remains intact. Thus, under experimental conditions, glucose and oxygen availability is most potently inhibited by reducing blood directly. Therefore, arterial occlusion and drastic blood pressure descents will most readily collapse the brain's energy metabolism.<sup>5</sup>

Hypoxic metabolic suppression occurs in a stepwise hierarchy with more elaborate electrophysiological and metabolic processes being impaired first. In that, the brain's intrinsic spontaneous electrical activity and protein synthesis will be halted more abruptly. In a severe hypoxic state, cerebral energy use loses capacity along with membrane depolarization.<sup>5</sup> For perspective, cell death occurs within five minutes of low oxygen and progresses to brain death after ten minutes. The hippocampus, the dorsolateral caudate and the thalamus' reticular nucleus are cited to be most susceptible to hypoxic injury. Prolonged hypoxia and the ensuing ATP depletion lends causality to disordered calcium homeostasis producing a vicious cycle of aberrant glutamate-mediated excitotoxicity and oxidative damage from free radicals. Consequently, neuronal apoptosis and necrosis result.<sup>4,5</sup> Under correct circumstances, any brain region may be affected.

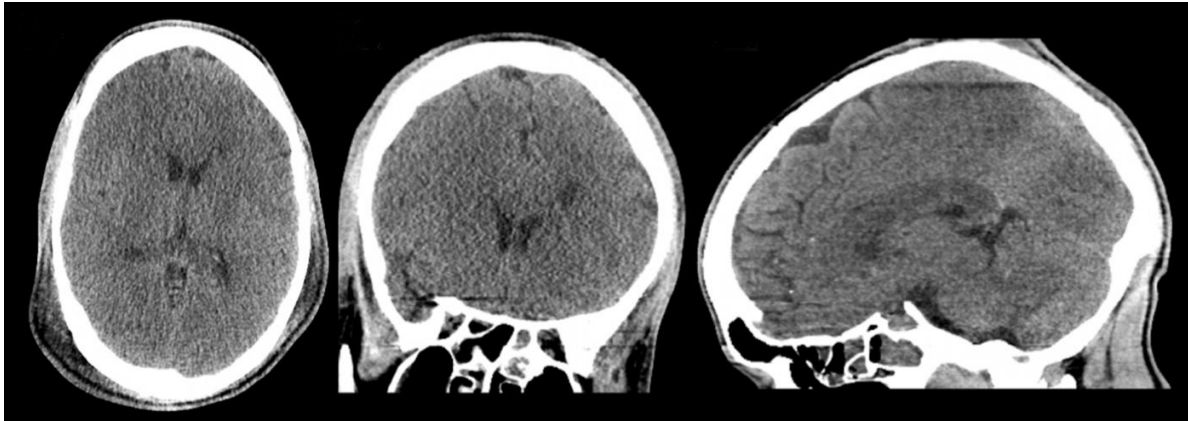
At the surface level, necrosis differs from apoptosis as defined by morphological characteristics. Apoptosis is known to invoke a more controlled program of cellular death reliant on gene expression and death-signaling proteins to recruit proteolysis via caspase enzymes. Juxtapose this with necrosis, reminiscent of cellular explosion caused by complications in ionic flux. Hypoxia-

ischemia in neurons will most usually cause necrosis rather than apoptosis.<sup>6</sup> Contemporary research cites ordered caspase activation to be similarly involved in neuronal necrosis, perhaps due to calcium-mediated mitochondrial cytochrome c release; independent of both gene expression and protein synthesis.<sup>6</sup> Nonetheless, liquefactive necrosis predominates in brain tissue, naturally insinuating cortical deficits. Pertinent example being that diffuse necrosis of the occipital lobe, involving the primary visual cortex, will befall cortical blindness



## Methods

The present study aims to highlight a rare case of cortical blindness in a gunshot victim. The subject, at the time, a 23-year-old male, sustained three bullet wounds: to the left chest- through the lung, to the right abdomen- inferior to the liver and to the right forearm. Throughout the course of his four-month hospital stay, the patient spent two months in ICU during which he experienced cardiorespiratory arrest two times, entering into a coma for two weeks. The subject was intubated and ventilated during this time, needing dialysis. The patient underwent four total ex-laps during his hospital stay. He reportedly suffered a loss of cerebral perfusion, precipitating multiple hypoxic seizures and permanent complete vision loss- for over two years thus far- which was noticed upon waking from the coma. Head CT was obtained revealing diffuse anoxic edema [Figure 1]. Confirmatory MRI could not be done due to projectile remnant. Prior to hospitalization, the patient reported no issues with vision nor any history of epilepsy. Despite vision loss, recent ophthalmological exam revealed PERRL [Figure 2], but with no elicitation of optokinetic nystagmus and was otherwise unremarkable-characteristic of cortical blindness.

The goal in writing this case study is to provide documentation of the relatively rare condition of cortical blindness, even more unusual given the so far permanent, perioperative and postictal circumstances. Insight extends into neuroanatomical structure and pathophysiology. The patient's devastating incident is further contextualized statistically. Importantly, rehabilitation is also addressed, on both the physical and psychological front for both victims of shootings and of vision loss.



**Figure 1.** Brain images demonstrate diffuse anoxic edema as represented by increased attenuation on CT imaging in axial (A), coronal (B), and sagittal (C) planes

Main Ophthalmology Exam		
External Exam		
	Right	Left
External	Normal	Normal
Slit Lamp Exam		
	Right	Left
Lids/Lashes	Normal	Normal
Conjunctiva/Sclera	White and quiet	White and quiet
Cornea	Clear	Clear
Anterior Chamber	Deep and quiet	Deep and quiet
Iris	Round and flat	Round and flat
Lens	Clear	Clear
Fundus Exam		
	Right	Left
Vitreous	Normal	Normal
Disc	Normal	Normal
Macula	Normal	Normal
Vessels	Normal	Normal
Periphery	Normal	Normal
Pupils		
	Pupils	
Right	PERRL	
Left	PERRL	
Visual Fields (Counting fingers)		
	Left	Right
		
Extraocular Movement		
	Right	Left
	Full	Full

**Figure 2.** Patient’s ophthalmological exam demonstrating intact eyes yet complete loss of visual fields

**Ethical considerations**

The study was conducted in accordance with the Declaration of Helsinki. The patient provided verbal consent to use images and clinical data for publication.

**Discussion**

Cortical blindness is defined by vision loss in the absence of ophthalmological insult, as aforementioned. Pupillary light reflexes remain intact and oculomotor function is



preserved, denoting spared eyes. To confer a full cortical blindness, bilateral lesions are typically inflicted upon the striate cortex or otherwise; the optic radiations caudal to the LGB. Cortical blindness inducing lesions may be caused by a plethora of conditions: stroke, occipital trauma, congenital abnormalities, hypoglycemia and infection are among the more common.<sup>1</sup> A typical case of secondary cortical blindness is presented alongside signs of parieto-occipital stroke. The condition is known to resolve spontaneously given that the inciting factor is removed. Spatial and depth perception impairment may, however, linger.<sup>7</sup> Cases of perioperative hypoxic cortical blindness remain uncommon. Even so, perioperative ischemic precautions must not be overlooked. In accordance with nonmaleficence, anesthesiologists and surgeons must take care to ensure ample hematocrit and intravascular volume in the OR.

In a study analyzing postoperative visual loss,<sup>8</sup> patients who underwent spinal surgery were retrospectively selected. 83 out of the 93 patients with vision loss were diagnosed with ischemic optic neuropathy. Notably, at least 1,000 ml of blood loss or an anesthetic duration of at least six hours characterized 96% of these cases. This etiology of vision loss may be distinguished clinically from cortical blindness on the basis of absent pupillary light reflexes. The remaining ten patients' blindness was attributed to central retinal artery occlusion- of an etiology dissimilar from blood loss.

Again, cases of post-op cortical blindness are rarely documented. Risks of hypoperfusion all-the-same remain. For the purpose of this case study, in which the patient reportedly experienced hypoxic seizures, the phenomenon of postictal blindness will be further examined. Earlier, a link between hypoxic ATP depletion and glutamate excitotoxicity was established.<sup>4,5</sup> On these grounds of excitotoxicity and with further research findings, we continue.

Epileptic seizures associated with acute hypoxia are frequently in the setting of neuronal ischemic necrosis.<sup>9</sup> The manifestation, clinically, is akin to an idiopathic epilepsy. Morphologically, development of hypoxic seizures becomes correlated with foci of cerebral softening referred to as encephalomalacia, the outcome of

liquefactive necrosis. Furthermore, past studies illustrate that chronic hypoxia may increase neuronal excitability, causing a predisposition for seizure disorder.<sup>9</sup> Demonstrating a clinical correlation between these two overarching conditions hints at possible preventative measures in the face of epilepsy and downstream consequences.

A 1983 study considers cerebral hypoxia the likely mechanism prompting cortical blindness in five select grand mal seizure patients.<sup>10</sup> The patients' etiologies are as follows: idiopathic epilepsy, vascular accident, brain cyst, acute encephalitis and chronic encephalitis. Four out of the five patients recovered sight after several days. Yet, the patient with idiopathic epilepsy remained completely blind up until death. The patient detailed was a 33-year-old woman with a history of grand mal seizures starting at age 18. Her cortical blindness was preceded by an episode of status epilepticus. It is worth noting that some patients with cortical blindness, including this permanent patient, deny their blindness. Still, they are found unresponsive to visual stimuli without elicitation of optokinetic nystagmus. A patient's denial or unawareness to their complete blindness, despite glaring evidence, is referred to as Anton syndrome. Due to Anton syndrome, cortical blindness may, at times, go unrecognized and under-reported. Close attention to the patient's presentation and history will limit misdiagnoses of conversion disorder or malingering. Keep in mind Anton syndrome as well as some differential diagnoses, such as; hemineglect, prosopagnosia and Bálint's syndrome.

Anton Syndrome may also be called Anton-Babinski syndrome. The condition presents as a visual anosognosia. The term "anosognosia" denotes a cognitive lapse in understanding rendering the patient completely unaware of the condition. Confabulation is expected, meaning that the patient will fabricate alternative explanations without realizing the falsity in their own logic. The syndrome at large appears in an absence of eye abnormalities and is commonly caused by PCA infarction. Anton syndrome's etiological similarities to cortical blindness may explain its potential for co-occurrence.<sup>11</sup>

Spatial neglect syndrome, also known as unilateral or hemineglect syndrome, is disabling in both sensory and

motor function. This disorder may present itself as perceptual, representational, visuospatial, or behavioral inadequacies. Spatial neglect coincides with anosognosia; given the patient's unaware state and the subtle nature of this condition, recognizing the syndrome clinically is a challenge. Spatial neglect syndrome most generally presents as contralateral visuo-spatial deficit following injury to the non-dominant cerebral hemisphere, more specifically the posterior parietal cortex. The pathology is most commonly seen after a hemispheric stroke of the MCA, but may also be caused by traumatic brain injury, neoplasm or aneurysm. The imbalance between cerebral hemispheres causes the non-damaged side to become more active than the latter; this can be observed in attentional dominance toward the intact visual field.<sup>12</sup>

Prosopagnosia represents a very specific cortical visual deficit as it pertains solely to facial recognition. A patient with prosopagnosia loses the ability to recall a familiar face and cannot form new recognition of one recently encountered. The condition may be acquired due to brain injury from direct trauma, PCA stroke, encephalitis, resections, atrophy, or tumors. Possible also, is a patient who presents with prosopagnosia at birth due to developmental abnormality of the occipito-temporal lobe.<sup>13</sup>

Bálint's syndrome presents as a triad characterized by optic ataxia, oculomotor apraxia and simultagnosia. Ataxia manifests as a compromised connection between visual input and motor output. As such, the patient's optic ataxia refers to an inability to perform a visually guided task. Interestingly, if provided with an audio cue, the patient may successfully complete a reaching task. The ataxia is posited to arise from damage to the superior parietal lobule: the proposed site for the relevant integrative coordination. An oculomotor apraxia impairs a patient's ability to shift gaze in the presence of intact extraocular muscles. Bilateral parietal lesions as well as lesions to the frontal eye fields may lead to the apraxia. Lastly, simultagnosia describes the inability to see the forest for the trees. Quite literally, only individual trees may be attended to while the overarching concept of a forest is lost. Viewing more than one object simultaneously becomes impossible, meaning that this

attentional deficit suggests a functionally blind patient. Bálint's syndrome is caused by bilateral parietal and occipital lesions, most commonly resultant of ischemic infarction.<sup>14</sup>

The descriptor, "cortical blindness" (CB), applies to any homonymous visual deficit resulting from a post-chiasmal lesion. Usually, the deficits present unilaterally. There is a dearth of epidemiological data regarding cortical blindness. Still, one study cites CB to be prevalent in 0.8% of the non-institutionalized Australian population over 49-years-old. Meanwhile, UK studies posit that visual deficits affect 28-52% of stroke survivors. A US study backs that up with a comparable incidence of 27-57% in a population of patients with ischemic brain injury.<sup>15</sup> In the realm of our perioperative blindness case, analysis follows. A retrospective Mayo Clinic study demonstrated,<sup>16</sup> with data from 410,189 patients, that only four patients experienced vision loss lasting greater than 30 days following noncardiac surgeries in which no optic or cerebral tissue was damaged. Two patients were diagnosed with ischemic optic neuropathy (ION) while the other two had occipital lobe infarcts precipitating CB. Another Mayo Clinic retrospective<sup>17</sup> pertained to 27,915 cardiopulmonary surgeries in which 17 patients were identified with prolonged vision loss from ION. 13 of the 17 were cited to have hemoglobin values of < 8.5 g/dL post-op.

On compiling statistics regarding expected recovery from CB, mixed evidence suggests a variable prognosis. In one such prospective study,<sup>18</sup> 69 patients with PCA infarction suffered complete homonymous hemianopia (HH). Kinetic perimetry testing revealed that 32 patients (47.8%) improved. Another prospective study<sup>19</sup> demonstrates spontaneous melioration of CB during the initial four weeks after injury. Here, 99 patients were admitted with clinical signs of HH from stroke. The serial examinations that follow over a 28-day period show full recovery of vision in 14 of the 81 (17%) complete HH patients. Meanwhile, 13 of the 18 (72%) patients with partial HH experienced full recovery. Data suggests poor prognosis in more complicated cases. A more encompassing prospective study<sup>20</sup> involving 254 homonymous hemianopia cases of mixed etiology used automated perimetry for observation. 38.4% of the stroke, trauma and

tumor patients displayed a spontaneous full recovery. Moreover, the likelihood of overall improvement was shown to relate to the time frame. Participants exhibited at least 50% chance of improving when tested within the first month. This value precipitously dropped to roughly 20% when tested at 6 months. From there, any and all improvements were null.

Overarching consensus appears to suggest that CB patients do indeed see improvements, however; the improvements were bound to an early period after onset. An earlier period than the present case study, in which CB has persisted over two years' time. Regrettably, given albeit limited evidence, the odds of our patient's visual recovery are low. Nonetheless, surely not all hope is to be lost on the rehabilitative front.

### Rehabilitation

Impaired mobility after a gunshot wound necessitates physical rehabilitation. Importantly, one must also appreciate any potential mental trauma. Seeking professional counseling can help identify PTSD. Beginning the journey aimed at alleviating day-to-day interference opens an avenue for improving stress and sleep management and offers resources designed to foster an active support group. In the context of a corroborative community, an individual's physical health and wellbeing will see positive change.

Vision impairments currently affect 2.2 billion individuals worldwide, naturally, adaptation becomes key. Hardships arise financially, socially and existing medical conditions stand to worsen in the absence of proper support. Luckily, acceptance and commitment therapy encourage a headstrong approach to problem solving. To begin, establishing a system for organization and structure is found to be efficient. Such that labeling household items becomes a substantial boon to quality of life; braille and read-aloud text are two available options. Read-aloud text may be better suited for a private setting, but bone conduction headphones allow for higher versatility. And learning braille may prove challenging, but the speed at which one acclimates is entirely dependent on the patient, their support system and their outlook- gaining a functional understanding can be accomplished in a few months. Concurrently, the use of canes and guide dogs

offers a more reasonable learning curve and grants a degree of independence. Those taking medications may implement talking and/or braille prescription labels. Talking prescription labels read aloud all prescription information and instructions, avoiding medical mishaps. Additionally, in the way of societal integration, The Bureau of Engraving and Printing provides a currency device to assist in identifying currency denominations for the eligible blind in the US.

Rehabilitation is a transient state. With the right resources and allocations of said resources, one can lead a full life notwithstanding a traumatic incident. The subject of the present study has been advised on the existing paths to healing and his steps tread toward recovery

### Conclusions

Care for the patient with cortical blindness is tantamount to understanding. The unintuitive nature of this condition must not exacerbate patient burden by way of misinterpretation to malingering, for example. Rather, positive rehabilitative efforts become inextricable to proper care. Setting realistic patient-centered goals requires analysis of inciting factor as well as time frame. On the etiological end, avoiding the circumstance altogether is easier said than done. Regardless, perioperative mindfulness remains critical with special consideration toward hemodynamic stability. Furthermore, close attention to health and environmental risk factors is encouraged always.

The subject of this present study, although aware of his vision loss, presents similarly to the aforementioned patient with idiopathic epilepsy and CB.<sup>10</sup> Notably still, the present case has no prior history of seizure disorder, yet still presents with cortical blindness postictally. Hence why we suggest the etiology of hypoxic seizure.

Moving forward, physical as well as psychic rehabilitation is recommended for this patient. The emotional toll, the physical toll and the socioeconomic impairment affect both the patient and his family. The consequent strain must not be overlooked in the treatment of patients with cortical blindness and victims of violence at large. It is paramount to assist a patient's coping all the while providing rehabilitative care. Need for more

nuanced demographic material on cortical blindness may be essential to fully appreciate the topic. Identifying and strengthening those at risk may bolster preventative measures for incidence.

### Acknowledgment

None.

### Competing interests

The authors declare that they have no competing interests.

### Abbreviations

Relative Afferent Pupillary Defect: RAPD;

Lateral Geniculate Body: LGB;

Cerebral Blood Flow: CBF.

### Authors' contributions

All authors read and approved the final manuscript. All authors take responsibility for the integrity of the data and the accuracy of the data analysis.

### Funding

None.

### Availability of data and materials

The data used in this study are available from the corresponding author on request.

### Ethics approval and consent to participate

The study was conducted in accordance with the Declaration of Helsinki. The patient provided verbal consent to use images and clinical data for publication.

### Consent for publication

By submitting this document, the authors declare their consent for the final accepted version of the manuscript to be considered for publication.

### References

1. Sarkar S, Tripathy K. Cortical Blindness. [Updated 2023 May 23]. In: StatPearls [Internet]. Treasure Island (FL): StatPearls Publishing; 2023
2. Rodrigues EM, Isolan GR, Becker LG, Dini LI, Vaz MA, Frigeri TM. Anatomy of the optic radiations from the white matter fiber dissection perspective: A literature review applied to practical anatomical dissection. *Surg Neurol Int* 2022;13:309. doi:10.25259/SNI\_1157\_2021 PMID:35928310 PMCID:PMC9345124
3. Huff T, Mahabadi N, Tadi P. Neuroanatomy, Visual Cortex. [Updated 2022 Jul 25]. In: StatPearls [Internet]. Treasure Island (FL): StatPearls Publishing; 2023.
4. Belov Kirdajova D, Kriska J, Tureckova J, Anderova M. Ischemia-Triggered Glutamate Excitotoxicity From the Perspective of Glial Cells. *Front Cell Neurosci*. 2020;14:51. doi:10.3389/fncel.2020.00051

- PMid:32265656 PMCID:PMC7098326
5. Hossmann KA. The hypoxic brain. Insights from ischemia research. *Adv Exp Med Biol*. 1999;474:155-69 doi:10.1007/978-1-4615-4711-2\_14 PMID:10635000
  6. Niquet J, Baldwin RA, Allen SG, Fujikawa DG, Wasterlain CG. Hypoxic neuronal necrosis: protein synthesis-independent activation of a cell death program. *Proceedings of the National Academy of Sciences*. 2003;100(5):2825-30. doi:10.1073/pnas.0530113100 PMid:12606726 PMCID:PMC151425
  7. Grover V, Jangra K. Perioperative vision loss: A complication to watch out. *J Anaesthesiol Clin Pharmacol*. 2012;28(1):11-6. doi:10.4103/0970-9185.92427 PMID:22345938 PMCID:PMC3275941
  8. Lee LA, Roth S, Posner KL, Cheney FW, Caplan RA, Newman NJ, Domino KB. The American Society of Anesthesiologists Postoperative Visual Loss Registry: analysis of 93 spine surgery cases with postoperative visual loss. *Anesthesiology*. 2006;105(4):652-9;867-8. doi:10.1097/0000542-200610000-00007 PMid:17006060
  9. Xu Y, Fan Q. Relationship between chronic hypoxia and seizure susceptibility. *CNS Neurosci Ther*. 2022;28(11):1689-1705. doi:10.1111/cns.13942 PMID:35983626 PMCID:PMC9532927
  10. Sadeh M, Goldhammer Y, Kuritsky A. Postictal blindness in adults. *J Neurol Neurosurg Psychiatry*. 1983;46(6):566-9. doi:10.1136/jnnp.46.6.566 PMid:6410006 PMCID:PMC1027452
  11. M Das J, Naqvi IA. Anton Syndrome. [Updated 2023 Apr 3]. In: StatPearls [Internet]. Treasure Island (FL): StatPearls Publishing; 2023
  12. Sarwar A, Emmady PD. Spatial Neglect. [Updated 2022 Aug 22]. In: StatPearls [Internet]. Treasure Island (FL): StatPearls Publishing; 2023
  13. Corrow SL, Dalrymple KA, Barton JJ. Prosopagnosia: current perspectives. *Eye Brain*. 2016;8:165-175. doi:10.2147/EB.S92838 PMid:28539812 PMCID:PMC5398751
  14. Parvathaneni A, M Das J. Balint Syndrome. [Updated 2022 Jun 27]. In: StatPearls [Internet]. Treasure Island (FL): StatPearls Publishing; 2023.
  15. Saionz EL, Busza A, Huxlin KR. Rehabilitation of visual perception in cortical blindness. *Handb Clin Neurol*. 2022; 184: 357-373. doi:10.1016/B978-0-12-819410-2.00030-8 PMid:35034749 PMCID:PMC9682408
  16. Warner ME, Warner MA, Garrity JA, MacKenzie RA, Warner DO. The frequency of perioperative vision loss. *Anesth Analg*. 2001; 93(6):1417-21. doi:10.1097/0000539-200112000-00013 PMid:11726416
  17. Nuttall GA, Garrity JA, Dearani JA, Abel MD, Schroeder DR, Mullany CJ. Risk factors for ischemic optic neuropathy after cardiopulmonary bypass: a matched case/control study. *Anesth Analg*. 2001;93(6):1410-6 doi:10.1097/0000539-200112000-00012 PMid:11726415
  18. And KT, Kolmel HW. Patterns of recovery from homonymous hemianopia subsequent to infarction in the distribution of the posterior cerebral artery. *Neuro-ophthalmology*. 1991;11(1):33-9. doi:10.3109/01658109109009640
  19. Gray CS, French JM, Bates D, Cartledge NE, Venables GS, James OF. Recovery of visual fields in acute stroke: homonymous hemianopia associated with adverse prognosis. *Age Ageing*. 1989;18(6):419-21. doi:10.1093/ageing/18.6.419 PMid:2629493
  20. Zhang X, Kedar S, Lynn MJ, Newman NJ, Biousse V. Natural history of homonymous hemianopia. *Neurology*. 2006;66(6): 901-5. doi:10.1212/01.wnl.0000203338.54323.22 PMid:16567709

#### Cite this article as:

Brod B, Patel T, Hargett R, Lebrun B, Ahmed S, Branly R, et al. Hypoxic brain trauma causing blindness in a multiple gunshot wound patient, a challenging clinical scenario with a brief review of the literature. *J Prev Complement Med*. 2024;3(1): 50-57. doi: 10.22034/NCM.2023.408036.1102